

A Case Study of *Ksharasutra* Therapy for the Management of *Naadivrana* (Pilonidal Sinus)

Mahesh Kumar*

*Assistant Professor, Department of Shalya Tantra, Ch. Brahm Prakash Ayurved Charak Sansthan Khera Dabar New Delhi, India.

ABSTRACT:

Naadivrana, commonly known as sinus is a chronic inflammatory condition primarily affecting the natal cleft region. The Pilonidal sinus (PNS) is very popular sinus disease seen in patients. Various treatment modalities have been described in the literature, including surgical excision, marsupialization, and *Ksharasutra* Therapy. *Ksharasutra* therapy is a minimally invasive Ayurvedic treatment, involves the use of medicated threads known for their potent wound healing properties. A case of 19-year-old male with a *Naadivrana* (typical Pilonidal Sinus) in the natal cleft region decided for *Ksharasutra* Therapy under *Ayurvedic* care. The *Naadivrana* (Pilonidal Sinus) was managed using *Ksharasutra* Therapy and *Ayurvedic* drugs. *Guggulu Ksharasutra*, a medicated thread impregnated with herbal alkaline compounds was inserted into the sinus tract. Over the course of treatment, the patient experienced gradual healing of the sinus tract with minimal discomfort. The *Ksharasutra* Therapy offers a promising alternative for the management of Pilonidal Sinus, especially in cases of recurrence or resistance to conventional treatments. The herbal alkaline compounds present in *Ksharasutra* exhibit potent antimicrobial and wound healing properties, facilitating the resolution of the sinus tract with minimal tissue damage. Further research and long-term studies are warranted to establish the efficacy and safety of *Ksharasutra* Therapy in the management of Pilonidal Sinus. The patient experienced complete healing of the sinus tract with no signs of recurrence at the six months follow-up, highlighting the efficacy and safety of *Ksharasutra* in the management of Pilonidal Sinus.

Keywords: Ayurveda, *Guggulu Ksharasutra*, *Ksharasutra* Therapy, *Naadivrana*, Pilonidal Sinus.

Received: 05.05.2024 Revised: 10.06.2024 Accepted: 18.06.2024 Published: 26.06.2024



[Creative Commons Attribution-NonCommercial-No Derivatives 4.0 International License](https://creativecommons.org/licenses/by-nc-nd/4.0/)

© 2024 International Journal of AYUSH Case Reports | Published by Tanaya Publication, Jamnagar.

Quick Response Code



*Corresponding Author:

Dr. Mahesh Kumar

Assistant Professor, Department of Shalya Tantra,
Ch. Brahm Prakash Ayurved Charak Sansthan Khera Dabar
New Delhi, India.

Email: drmkguptabhu@gmail.com

INTRODUCTION:

Pilonidal, the Latin literally meaning 'nest of hairs'. The Pilonidal sinus (PNS) is an inflammatory condition resulting from hair penetration into the epidermis, leading to the formation of sinus tracts lined with granulation tissue^[1]. *Naadvirana*, also known as Pilonidal Sinus (PNS), is a chronic inflammatory disorder primarily affecting the sacrococcygeal region^[2]. It is believed to occur due to the involution of hair into the epidermis, leading to the formation of sinus tracts. While PNS most commonly occurs in the sacrococcygeal region, in the cleavage between the buttocks (natal cleft). It can also be found in other areas such as the umbilicus, nose, suprapubic region, groin, interdigital web, and axilla, although these occurrences are rare^[3]. Clinical manifestations of Pilonidal sinus include pain, warmth, swelling, and the discharge of pus. It typically presents during puberty and adulthood, with males being affected more frequently than female^[4]. While the exact cause is unclear, it is believed to be triggered by factors such as hair penetration, skin wrinkling (such as in the natal cleft or scar tissue), hormonal influences, and pressure on unusual areas. Risk factors include excessive hair, young age, male gender, prolonged sitting, deep navel and cleft, and poor personal hygiene^[5]. Diagnosis of typical PNS is usually straightforward. The PNS easily diagnosed by clinical methods however in some cases radiological investigations like Sinogram, MRI, USG may require to find the exact direction and extent of tract^[6].

The modern Pilonidal Sinus disease is closely resembling with Ayurvedic disease *Shalaya-janya Naadi-vrana or Naadi-vrana*^[7]. The *Ksharasutra Therapy* advised by *Aacharya Sushruta* is now a popular treatment method practiced for its management^[8]. *Ksharasutra Therapy* involves the use of a medicated

thread, prepared with herbal alkaline compounds, which is inserted into the sinus tracts to cut the tract and to promote healing^[9]. The case report highlights the efficacy of this traditional Ayurvedic treatment in the management of a condition that closely aligns with the clinical features of *Naadvirana* described in Ayurvedic texts.

PATIENT INFORMATION:

A 19-year-old male presented to the hospital with a complaint of pus discharge from the low back site between the gluteal cleft since one month. The onset is gradual with mild swelling and pain. He is a student by profession, with a sedentary lifestyle, non-smoker, and non-alcoholic. His past and family histories were unremarkable. There is no history of chronic illness, tuberculosis, hypertension, major surgery, or prolonged medication. He had sought prior consultation at an allopathic centre a week before presenting to our hospital, seeking better treatment through *Ksharasutra therapy*.

Clinical Presentation and Screening:

The patient presents with a discharging sinus accompanied by mild pain and bleeding in the sacrococcygeal region persisting for one month (Figure 1). Initial tests including complete blood count, blood sugar, clotting and bleeding time, as well as screening for HIV and Hepatitis B, showed normal results. Additionally, the patient's blood pressure, pulse rate, respiratory rate, temperature, and general condition were within normal ranges.

THERAPEUTIC INTERVENTION:

After screening the patient, the patient admitted in ward and pre-operative preparation was done. The patient prepared

for *Ksharasutra Therapy* in operation theatre (OT). The patient consent was taken, local part prepared with antiseptic solutions and infiltration of anaesthesia (plain lignocaine hydrochloride 2% injection) locally. With the help of mosquito artery forceps, the tuft of hairs removed [Figure 2] and clean the tract by sterile gauze piece. The *Ksharasutra* inserted in the tract with the help of cuppor probe (*Eshani Yantra*). The *Ksharasutra* tied and local part cleaned with antiseptic solution [Figure 3]. Full aseptic precautions were taken during the whole procedure. The procedure of therapy for excision of sinus adopted as described in *Sushruta (Sushruta chikitsa 17/30-33)* ^[10]. Furthermore, the Ayurvedic treatment regimen included the following medications such as *Kaishore Guggulu*, two tablets twice daily; *Kumarayasava* syrup, four teaspoons twice daily after meals

with an equal amount of water; and *Vidangadi Lauha* tablets, twice daily after meals with water. Daily dressing of the affected area was performed using *Jatyadi oil*, ensuring full aseptic precautions. The timeline of events during the whole course of therapy is mentioned below in Table 1.

Follow up and Outcomes:

The patient visited in follow up at hospital. Total 45 days therapy was done which includes weekly change of *Ksharasutra*, cleaning and dressing and assessment. At forty-five days complete cut through of PNS tract occur and wound become healthy within a week. With this therapy the pilonidal sinus tract completely healed (Figure 4). After six months, the scar was healthy, there was no sign of recurrence.

Table-1: Time line of the event:

Date	Event
29-06-2023	First time patient consulted for the disease by outside Doctor
04-07-2023	Patient visited our hospital in <i>Shalya</i> OPD for consultation.
05-07-2023	Patient admitted in surgery ward for <i>Ksharasutra Therapy</i>
05-07-2023	Surgical procedure i. e. <i>Ksharasutra Therapy</i> done
07-07-2023	Indoor care of patient done.
08-07-2023	Patient discharged from the hospital and prescribed the Ayurvedic drugs, cleaning of local site.
11-07-2023	Hospital visitation for follow up. Cleaning dressing and assessment
22-07-2023	Hospital visitation for follow up. Cleaning dressing and assessment
19-08-2023	Hospital visitation for follow up and assessment

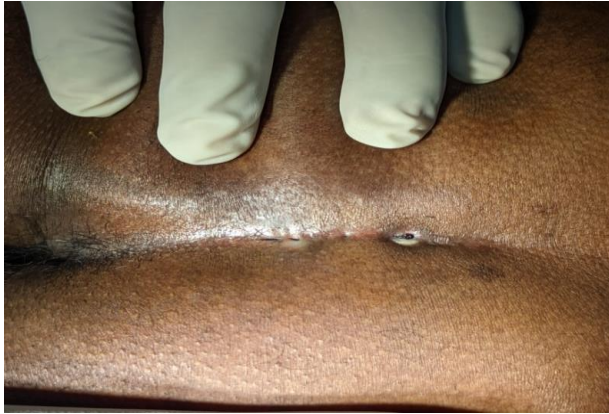

Figure-1: Clinical presentation of Pilonidal Sinus involving Sacrococcygeal region

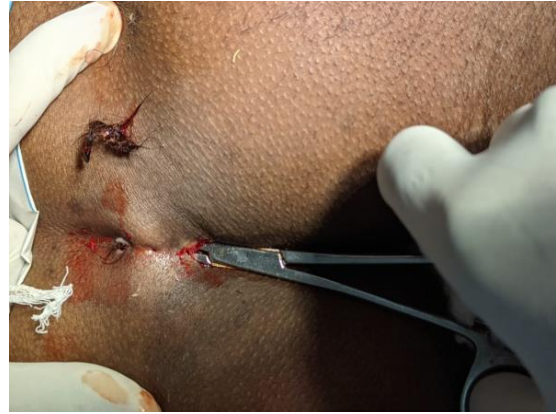


Figure-2: Removal of hair tufts from PNS tract.

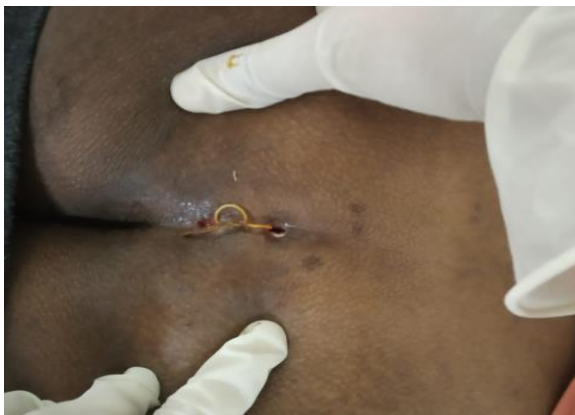

Figure-3: Ksharasutra application in PNS tract

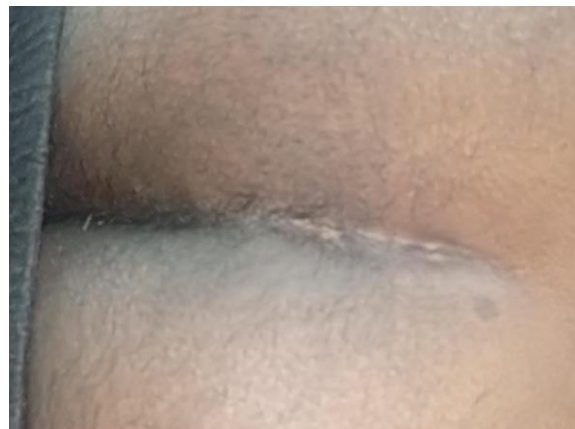

Figure-4: Completely healed PNS tract

DISCUSSION:

Despite various treatment options for pilonidal sinus, including surgery, outcomes are often unsatisfactory. In *Susbruta Sambhita Chikitsa sthana* chapter one (*Dwivraneeya Chikitsa* 1/104) have reference that if the wound cavity has hairs should be treated priority to remove the hairs with the help of *Kshura*, *Kartari*, *Sandansha Yantra*^[11]. After that the Vrana should be treated like normal vrana.

Acharya Susbruta advocates that the *Naadivrana* if founds in *Krishna* (emaciated), *Durrbal* (person with loss of physical strength), *Bheeru* (timid, coward) and reside at *Marma* site (vital point), expected to excise by *Ksharasutra* not by *Shastra* (sharp instruments) (*Susbruta Chikitsa* chapter 17/29)^[12]. Here

the clear indication of *Ksharasutra* in *Naadivrana* mentioned in ancient literature and same to same practiced in current scenario.

Kshara is very important drugs describe in Ayurveda having the property of *Chedana* (Excision), *Bhedana* (Incision), and *Lekhana* (Scraping)^[13]. The *Ksharavarti* and *Ksharasutra therapy* is indicated in *Naadivrana chikitsa* by *Acharaya Susbruta*^[14]. The *Ksharasutra therapy* works through its cutting, healing, and cleansing effects, as per Ayurveda principles. It cut and softens the sinus tract.^[15]

The *Ksharasutra* is inserted directly into the entire sinus tract, where the medicated alkaline thread dissolves the tough fibrosed tissues, aiding in the elimination of infections, hair, and infected tissue. The physical

presence of the thread and regular changes ensure the sinus tract remains open and effectively drains pus, including from the smallest branches, thereby reducing the chances of recurrence. This thorough drainage and comprehensive treatment of sinus branches easily not be achieved through simple excision of the sinus tract alone. The *Ksharasutra* works through both mechanical pressure and chemical cauterization ^[16]. Additionally, *Ksharasutra* therapy is minimally invasive, simple, safe, cost-effective, and facilitates a quick return to regular activities for patients. ^[17]

CONCLUSION:

Ksharasutra Therapy along with *Ayurvedic* medications shows promise in the management of Pilonidal Sinus disease, offering a minimally invasive and cost-effective treatment option. The clear indication for this therapy is found in *Sushruta Samhita* under the treatment of *Naadivrana*. By using *Ksharasutra* for *Chedana* of *Naadi*, it proves to be a definitive, day-care therapy that is highly effective and popular. This treatment not only minimizes the rates of complications and recurrence but also allows patients to return to normal activities sooner.

Ethical approval and Consent:

This is a case report. Consent has been taken from the patient.

Acknowledgement:

The author is thankful to the patient for informing, keeping in touch, and sharing the complete incidence. Thanks to authority, faculty and all staffs of department for their cooperation.

Conflict of interest: Author declares that there is no conflict of interest.

Guarantor: Corresponding author is guarantor of this article and its contents.

Source of support: None

How to cite this article:

Kumar M. A Case Study of Ksharasutra Therapy for the Management of *Naadivrana* (Pilonidal Sinus). *Int. J. AYUSH CaRe.* 2024;8(2): 196-201.

REFERENCES:

1. Sunkara A, Wagh D, Harode S. Intermammary pilonidal sinus. *Int J Trichology.* 2010 ;2(2):116-8.
2. Dr. Rajasree G, Dr. Anita K. Patel. A Review on *Salyajanya Nadi Vrana* (pilonidal sinus) with clinical approach. *J Ayurveda Integr Med Sci* 2019; 2:85-89.
3. Sunkara A, Wagh D, Harode S. Intermammary pilonidal sinus. *Int J Trichology.* 2010 ;2(2):116-8.
4. Nixon AT, Garza RF. Pilonidal Cyst and Sinus. [Updated 2023 Aug 8]. In: StatPearls [Internet]. Treasure Island (FL): StatPearls Publishing; 2024 Jan-. Available from: <https://www.ncbi.nlm.nih.gov/books/NBK557770/> [Last accessed on 14-06-2024 9.00 PM]
5. Harlak A, Mentos O, Kilic S, Coskun K, Duman K, Yilmaz F. Sacrococcygeal pilonidal disease: analysis of previously proposed risk factors. *Clinics (Sao Paulo).* 2010 ;65(2):125-31.
6. Nixon AT, Garza RF. Pilonidal Cyst and Sinus. [Updated 2023 Aug 8]. In: StatPearls [Internet]. Treasure Island (FL): StatPearls Publishing; 2024 Jan-. Available from: <https://www.ncbi.nlm.nih.gov/books/NBK557770/>. [Last accessed on 14-06-2024 9.00 PM]
7. Rajasree G., Anita K. Patel. A Review on *Salyajanya Nadi Vrana* (pilonidal sinus)

- with clinical approach. *Journal of Ayurveda and Integrated Medical Sciences*, 2019;4(02), 85-89.
8. Gowthami N, S.V Shailaja, Management of Pilonidal Sinus with Chitraka Kshara Sutra - A Case Study. *J Ayu Int Med Sci*. 2023;8(6):267-271.
 9. Dwivedi AP. Management of pilonidal sinus by Kshar Sutra, a minimally invasive treatment. *Int J Ayurveda Res*. 2010 ;1(2):122-3.
 10. Shastri Ambikadutta, Ayurved Tattva Sandeepika hindi commentary on Sushruta Samhita (Sushruta chikitsa 17/30-33), Chaukhambha Sanskrit SansthanVaranasi, reprint edition 2005, p- 81
 11. Shastri Ambikadutta, Ayurved Tattva Sandeepika hindi commentary on Sushruta Samhita (Sushruta Samhita Chikitsa sthana chapter one (*Dwivraneeya Chikitsa* 1/104), Chaukhambha Sanskrit SansthanVaranasi, reprint edition 2005, p-11.
 12. Shastri Ambikadutta, Ayurved Tattva Sandeepika hindi commentary on Sushruta Samhita (Sushruta Chikitsa chapter 17/29), Chaukhambha Sanskrit SansthanVaranasi, reprint edition 2005, p- 81.
 13. Hardik Variya, Hemant Toshikhane, Sathish H.S, Nilesh Jethava. A Literature Review: The Role of Kshara in Ayurveda. *AYUSHDHARA*, 2016;3(4):805-810.
 14. Shinde P, Toshikhane H. Pilonidal sinus (*Nadivrana*): A case study. *Int J Ayurveda Res*. 2010 Jul;1(3):181-2.
 15. Meena RK, Dudhamal T, Gupta SK, Mahanta V. Comparative clinical study of *Guggulu*-based *Ksharasutra* in *Bhagandara* (fistula-in-ano) with or without partial fistulectomy. *Ayu*. 2018 Jan-Mar; 39(1):2-8.
 16. Parmar G, Parmar M. Role of Kshar sutra karma in infected Pilonidal Sinus - A Case Study. *International Ayurvedic Medical Journal*. 2018; 6(6):1308-1310.
 17. Panigrahi Hemanta, Rana Rakesh Kumar, Rao MM. *Ksharasutra* therapy-a minimal invasive parasurgical method in the treatment of Sacrococcygeal pilonidal sinus (*Nadi vrana*): Result of a pilot study. *Int. J. Res. Ayur. Pharm*. 2012; 3(5):668-670.