

Effect of Unani Formulations in the Management of *Salaat E Rahem* (Uterine Fibroid) - A Case Report

Tuba Razi,^{1*} Fahmeeda Zeenat²

^{1*}PG scholar, ²Assistant Professor, Department of Amraz e Niswan wa Qabalat, Ajmal Khan Tibbiya College, A.M.U, Aligarh, UP, India

ABSTRACT:

Salaat e rahem (Uterine fibroid) lesions were initially known as the “uterine stone.” The term fibroid was first introduced in the 1860s. Uterine fibroids are prevalent pelvic tumours in women of reproductive age, affecting 20-50% of them based on age, ethnicity, parity, and assessment methods. They can occur as single or multiple focal fibroids or can be diffuse. After menopause, fibroids tend to contract. Surgery can be used to treat fibroid for urgent medical needs, but finding a medication without side effects remains challenging. In this case report, a 30-year-old patient presented with complaints of lower abdominal pain and irregular menstrual cycle. The USG confirmed presence of two solid masses in endometrium and multiple Nabothian cysts. Unani treatment was prescribed to her for three months. On follow ups her symptoms started to resolve. after three months USG was repeated which showed a normal scan with few Nabothian cysts. Through this article it can be concluded that uterine fibroids can be successfully treated with herbal preparations from Unani system of medicine.

KEY WORDS: *Majoon dabid- ul- ward, Salat- e -Rahem*, Unani medicine, Uterine fibroids.

Received: 02.04.2024 Revised: 30.04.2024 Accepted: 10.05.2024 Published: 26.05.2024



[Creative Commons Attribution-NonCommercial-No Derivatives 4.0 International License](https://creativecommons.org/licenses/by-nc-nd/4.0/)

© 2024 International Journal of AYUSH Case Reports | Published by Tanaya Publication, Jamnagar.

Quick Response Code



*Corresponding Author:

Dr. Tuba Razi

PG scholar,

Department of Amraz e Niswan wa Qabalat, Ajmal Khan

Tibbiya College, A.M.U, Aligarh, UP, India

E-mail: tubarazi30095@gmail.com

INTRODUCTION:

Fibroid, also known as uterine leiomyomas, myomas, or fibromyomas, is the most common benign uterine tumor in women, consisting of smooth muscles and fibrous connective tissues. Tumors affect 20-50% of women, particularly between 30-45 years old, and are more prevalent among African

women, influenced by age, ethnicity, and detection methods.^[1] Fibroid is a monoclonal, oestrogen-dependent tumor, primarily caused by progesterone and oestrogen. It typically appears after menarche and shrinks after menopause, typically in nulliparous or low parity patients.

In Unani literature tumours have been referred as "*Salaat*," which is a subtype of *Waram-e-Balghami* (phlegmatic swelling) [2] *Salaat* can be classified as benign (*salaat e saleema*) or malignant (*salaat e kbabeesa*). *Salaat e saleema's* growth is akin to the organ they are developing in. These are not associated with pain. The matter does not infiltrate the local nodes In Unani medicine uterine fibroids, also known as *salaat e rahem* are classified as *salaat e saleema*, it has been also mentioned by renowned Unani physicians that viscous phlegm (*balgham*) is the cause behind these *salaat*. The large fibroid can be dissolved by the medicines which have *Muhallil e waram* (resolvent), *munzij e balgham* and *qabiz* (astringent) property [3]. Soft swellings are treated directly with *Muhallil e waram* and *qabiz* drugs but firm swelling needs first *munzij e balgham* drugs to make the swelling soft followed by *Muhallil e waram* and *qabiz* drugs. [4]

Fibroids can be uterine and extrauterine. Uterine fibroids can be further classified as:

- **Intramural-** grows within the myometrial wall (M/C-75%)
- **Submucous** -grows towards the uterine cavity (15%)
- **Subserous**-grows outward towards the peritoneal surface-5%

FIGO classification [5]

- Type 0: pedunculate intracavitary (inside of the uterus)
- Type 1: <50% inside of the uterine cavity
- Type 2: >50% inside of the uterine cavity
- Type 3: contacts the endometrium, 100% in the wall of the uterus
- Type 4: intramural, completely inside the wall of the uterus
- Type 5: Subserosal, >50% intramural
- Type 6: Subserosal <50% intramural

- Type 7: pedunculated subserosal
- Type 8: other (e.g. cervical, parasitic)

Symptoms of Fibroids-

- Mostly asymptomatic.
- Most common symptom is progressive menorrhagia.
- Pressure symptoms
- Infertility
- Pain- usually does not cause pain but if it does it may be due to –
Malignancy, associated
endometriosis, torsion of
pedunculated fibroma,
degeneration [6]

CASE REPORT:

A 30-year-old female patient presented with lower abdominal pain, irregular menstrual cycle and clots in menstrual blood for the past 7 months at *Amraz e Niswan wa Qabalat* OPD, AKTCH, AMU. Clots were jelly like and brownish in colour (Fig-1). Pain was localised and persistent since last 1 year.

In her past history she had undergone caesarean section 4 years ago. At time of operation Cu T was inserted. The colour of lochia after a week of operation turned from reddish pink to rusty brown and consistency was thick. Amount of lochia was moderate and did not become less even after 3 months. After 3 months patient got removed the Cu T in a hospital following doctor's advice. After 1 year of her normal menstruation, she started having irregular menstrual cycle with jelly like clots in her menstrual blood, along with moderate to severe abdominal pain, which subsided only by taking analgesics.

In personal history- Bowel-regular; Appetite-good; Micturition-normal; Sleep-Sound

LMP (on first visit)- 24/4/2023
C/D/F-not fixed/7-9days/severe

ON EXAMINATION-

General examination

Systemic examination

BP - 110/80mmhg

CVS- S1, S2 audible, no added sounds heard

PR-102/min

R/S- B/L chest clear

SPO2-98%

GIT- lower abdomen tenderness present,

Temp.- afebrile

-No organomegaly

Oedema- negative

Pallor- mild present

P/S-White creamy discharge present,

- mouth of cervix appeared red (Fig.-2)

-cervix appeared congested

P/V- fornix clear, mild tenderness present

- Cervix with multiple Nabothian cysts approximately 6mm each in size.
- Two solid masses in endometrial canal approximately 3cm each.
- Both ovaries enlarged.

The menstrual history is mentioned in detail in table 2

THERAPEUTIC INTERVENTION-

The details about the treatment protocol are mentioned in (Table- 1),

1. Counselling of the patient about the reports and treatment plan.
2. *Majoon dabeed ul ward*
3. *Majoon zanjabeel*
4. *Arq e mako*
5. *Arq e Kasni*
6. *Niswani*

INVESTIGATIONS: USG done on 3/3/2023(before treatment) showed in (fig-3.)

Table- 1: Therapeutic Intervention:

Drug	Dose	Duration
<i>Majoon dabeed ul ward</i>	Half tsp BD	After breakfast, after dinner × 3 months
<i>Majoon zanjabeel</i>	Half tsp BD	After breakfast, after dinner × 3 months
<i>Arq e mako</i>	60 ml BD	After breakfast, after dinner × 3 months
<i>Arq e Kasni</i>	60 ml BD	After breakfast, after dinner × 3 months
<i>Niswani</i>	20 ml BD	After breakfast, after dinner×3 months

Table 2: Menstrual History:

Menstrual history	Past	At first visit (before treatment)	After treatment
Cycle	Regular	Irregular	regular
Interval	25-28 days	Not fixed	28-30 days
Duration	4-5 days	7-9 days	5-6 days
Flow	Mild	moderate with clots	moderate
Pain	Severe	Persistent daily	Mild
Clots	NIL	Jelly like	NIL

Table -3: Comparative USG Findings:

USG on 3/3/2023 before treatment	<ul style="list-style-type: none"> • Multiple Nabothian cysts in cervix approx.6 mm in size. • Two solid masses in endometrium approx..3cm in size. • B/L ovaries enlarged.
USG on 22/8/2023 after treatment	<ul style="list-style-type: none"> • Few Nabothian cysts of approx. 4mm • No focal or diffuse mass lesion seen in endometrium. • B/L ovaries normal shape and size.

Table -4: Result:

Parameters	Before Treatment	After Treatment
USG findings	Two solid masses in endometrial canal - 3cm approx.	NIL
Cycle	Irregular cycle	Regular
Flow of menstruation	severe	moderate
Interval	not fixed	28-30 days fixed
Clots	Clots - +++ jelly like	NIL
Lower abdominal pain	moderate to severe, persistent	NIL

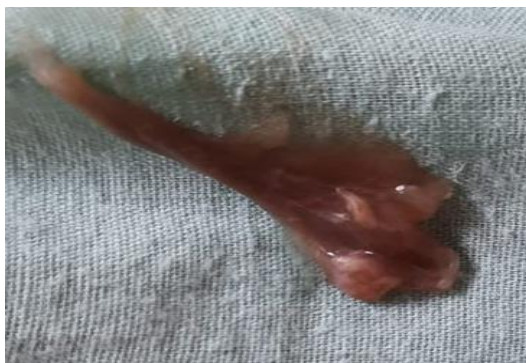

Figure-1: Clot in menstrual blood

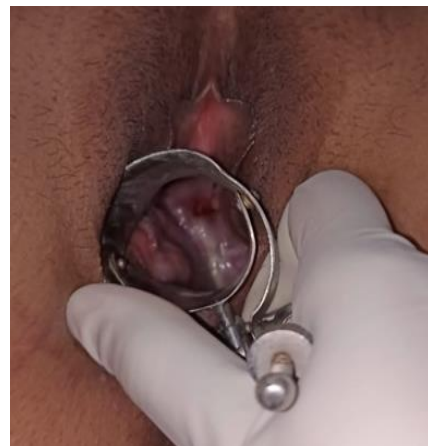

Figure-2: Red cervix with white creamy discharge

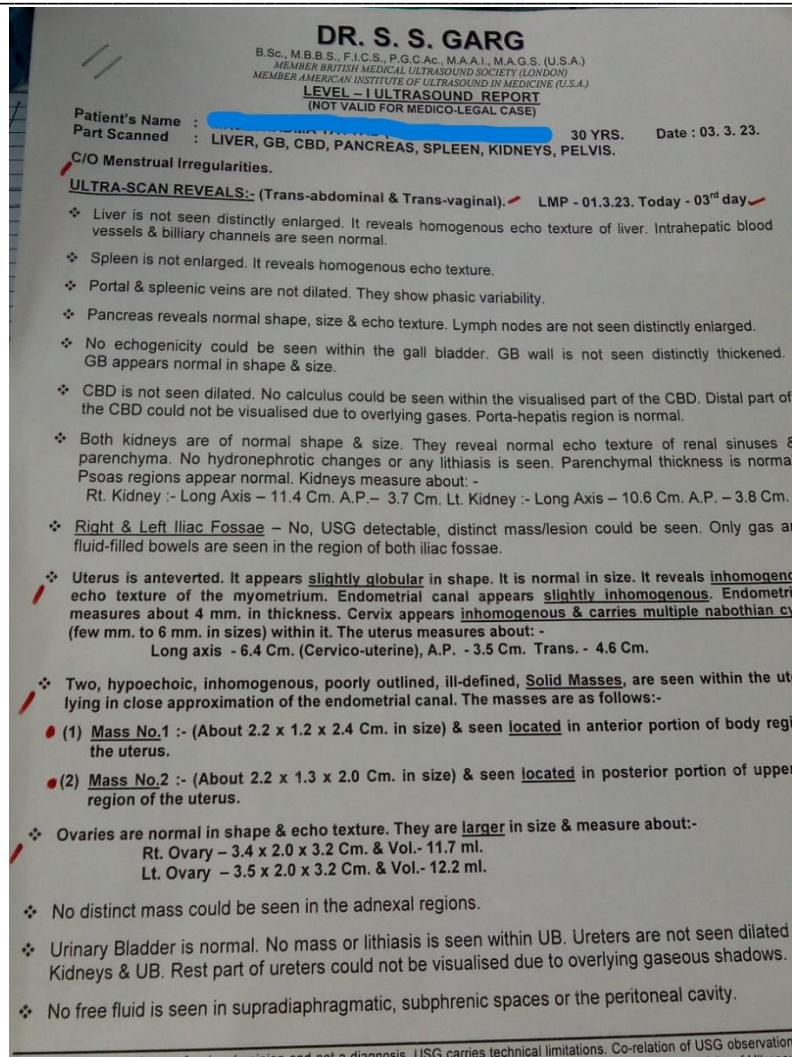


Figure-3: USG before treatment

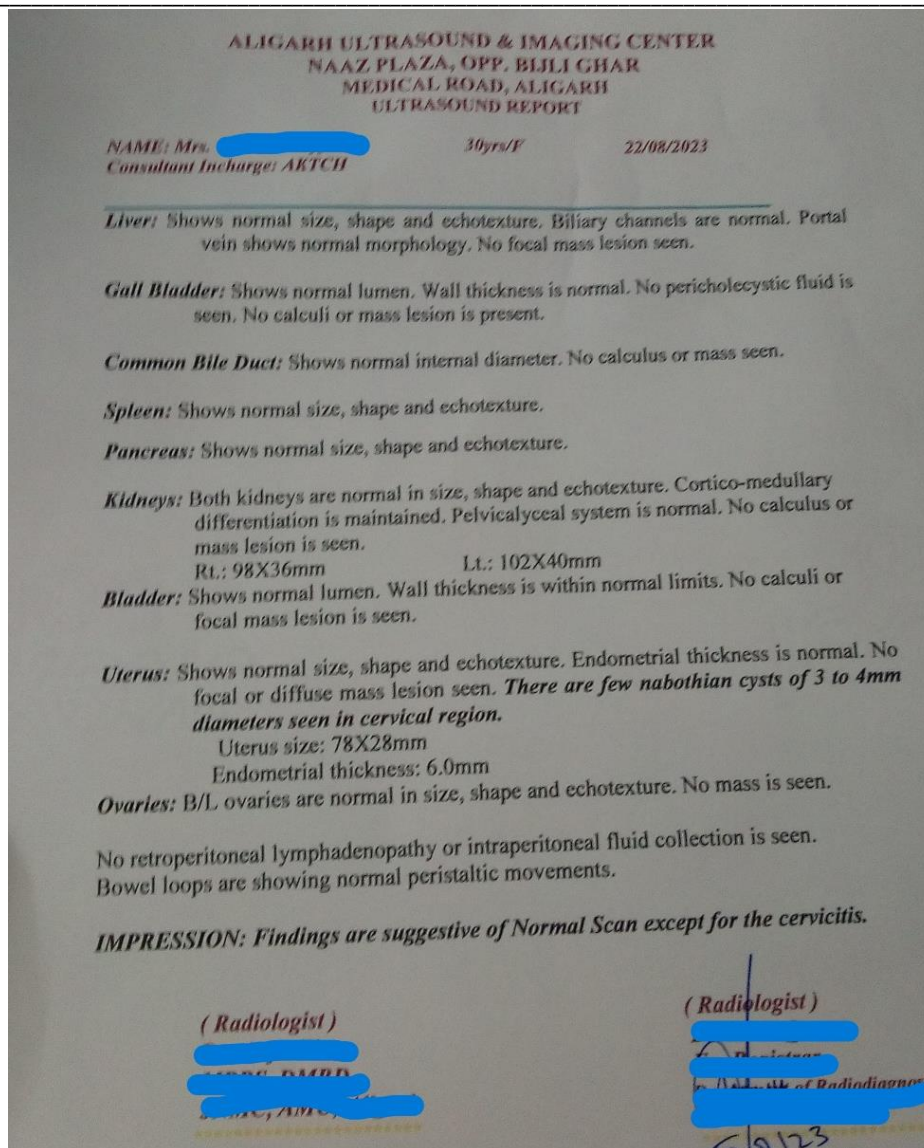


Figure-4: USG after treatment

RESULT:

After starting treatment her cycles got regular with moderate menstrual bleeding. After completion of treatment other associated complaints like general weakness, fatigue and pain, etc. also got subsided. Comparison between before study and after study is made in (Table 4).

Repeat scan was done to see the reduction in the size of fibroid, but it suggested of normal scan (Fig.4). (Table 3). Fibroid was completely resolved. Following treatment, the patient was monitored for two cycles for the recurrence of symptoms. No negative effects were observed in the patient.

DISCUSSION

Majun Dabeed ul Ward is recommended in inflammation and the swelling of uterus^[7,8] The main ingredient in *Majun Dabeed ul Ward*, *Rosa damascene*, has analgesic and anti-inflammatory properties. In mice tested with formalin and acetic acid, it has been shown that *Rosa damascene* hydroalcoholic extract has a strong analgesic effect.^[9]

The other main ingredient, *Zafran* (*Crocus sativus*), has antioxidant, anti-tumour, and anti-proliferative properties. In mice with intraperitoneally transplanted s

arcoma 180 (S180), Ehrlich ascites carcinoma (EAC), and Dalton's lymphoma ascites (DLA) tumors, Nair et al. investigated

the anticancer efficacy of saffron (*Crocus sativus*) extract^[10]. The primary sources of antioxidant activity were identified as carotenoid and flavonoid molecules, including the glycosides of kaempferol and crocin^[11]

Swiss mice and albino rats were used as test subjects for the anti-inflammatory and analgesic effects of *Zingiber officinale* rhizome extract, respectively. The findings indicate that *Z. officinale* rhizome extract contains one or more analgesic and anti-inflammatory agent(s).^[12]

Niswani Syrup is highly efficacious in the irregularities of menstrual cycle, Wang et al examined the cytotoxic and antitumor effects of Curzerene from *Curcuma longa* (*Haldi Zard*) in both in vitro and in vivo models. It was showed that tumour growth was significantly inhibited the proliferation of SPC-A1 human lung adenocarcinoma cells line by using curzerene (135 mg/kg daily), this effect is mediated via down regulation of GSTA1 protein and expressions of mRNA.^[13]

Post-e Amaltas (*Cassia fistula* bark) possess anti-inflammatory and antioxidant activities. It is reported that the aqueous (CFA) and methanolic extracts (CFM) of the *Cassia fistula* bark extracts showed significant radical scavenging by inhibiting lipid peroxidation; may be due to presence of polyphenolic content^[14] *Post-e-Arjun* (*Terminalia arjuna* bark) also possess antioxidant, anti-inflammatory and immunomodulatory activities. It is studied that aqueous extracts of *T. arjuna* showed significant inhibition activity of CYP3A4, CYP2D6 and CYP2C9 enzyme^[15] *Ashoka* (*Saracaindica*) dried bark is used as a tonic or stimulant to the endometrium and

ovarian tissue.^[16] *Khurma* (*Phoenix dactylifera*) possesses anti-neoplastic effect. Ishurda et al observed a dose dependent anticancer activity with an optimum activity at a dose of 1mg/kg of body weight in mice bearing sarcoma – 180 solid tumours.^[17]

CONCLUSION:

Hence it can be concluded that further studies should be carried out on *majoon dabid ul ward* to find out its efficacy in treatment of fibroids and other tumors. It is need of the hour to find out solutions to shaking health system through nature.

Consent of patient: Consent was taken from the patient before starting the treatment protocol as well as prior to publication of the case details and images without disclose the personal identity.

Conflict of interest: Author declares that there is no conflict of interest.

Guarantor: Corresponding author is guarantor of this article and its contents.

Source of support: None

How to cite this article:

Razi T, Zeenat F. Effect of Unani Formulations in the Management of *Salaat E Rahem* (Uterine Fibroid) – A Case Report. *Int. J. AYUSH CaRe.* 2024;8(2): 226-233.

REFERENCES:

1. Simms-Stewart D, Fletcher H. Counselling Patients with Uterine Fibroids: A Review of the Management and Complications. *Obstetrics and Gynecology International.* 2012;2012:1–6.
2. Hamdani HSKH. *Usoole Tib.* 3 rd ed. New Dehli: Qaumi Council Baraye Farogh Urdu Zaban; 2006, p- 140.

3. Bughdadi IH. Kitab al Mukhtarat Fil Tib. Part I. New Delhi: CCRUM; 2005: 294.
4. Tabri R. Firdos al Hikmat. Deoband: Faisal Publications; 2002: 299.
5. Munro MG, Critchley HOD, Broder MS, Fraser IS. FIGO classification system (PALM-COEIN) for causes of abnormal uterine bleeding in nonpregnant women of reproductive age. *International Journal of Gynecology & Obstetrics*. 2011;113(1):3–13
6. Konar H. D.C Dutta's textbook of obstetrics including perinatology and contraception. Kolkata, India: New Central Book Agency; 2011.
7. Anonymous, Disease & Treatment. Hamdard (waqf) Laboratories (India), New Delhi. 2009. p-31.
8. Kabeeruddin HM. Beyaz-e-Kabeer. 2nd vol. Hikmat Book Depo, Haiderabad Deccan: 2004. p 132.
9. Hajhashemia V, Ghannadib A, Hajilooa M. Analgesic and Anti-inflammatory Effects of Rosa damascene Hydroalcoholic Extract and its Essential Oil in Animal Models. *Ira J Phar Res* 2010; 9(2):163-68.
10. Nair SC, Pannikar B and Panikkar KR. Antitumour activity of saffron (*Crocus sativus*). *Cancer Lett* 199;57(2):09-114.
11. . Ali Esmail Al-Snafi AE. The pharmacology of *Crocus sativus*- A review. *IOSR J Pha* 2016;6(6):08-38.
12. Raji Y, Udoh U S, Oluwadara O, Akinsomisoye O S, Awobajo O, AdeshogaK. Anti-inflammatory and Analgesic properties of the rhizome extract of *Zingiber officinale*, *Afr J Biomed. Res*,2002;5:121-124.
13. Wang Y, Li J, Guo J, Wang Q, Zhu S, Gao S, et al. Cytotoxic and Antitumor Effects of Curzerenone from *Curcuma longa*. *Planta Med* 2017; 83 (1-2); 23-29
14. Ajay Kumar K, Satish S, Sayeed I et al. Therapeutic Uses of *Cassia Fistula*: Review. *Int J Pha Chem Res* 2017; 3(1): 38-43
15. Amalraj A, Gopi S. Medicinal properties of *Terminalia arjuna* (Roxb.) Wight & Arn.: A review. *J Trad Complem Med* 2017;7:65-78
16. Mishra A, Kumar A, Rajbhar N, et al. Phytochemical and Pharmacological Importance of *Saraca indica*. *Int J Pharmac ChemSci*2013; 2 (2):1009-13.
17. Ateeq A, Sunil SD, Varun SK, Santosh MK. *Phoenixda ctylifera* Linn. (Pind Khajura)- A Review. *Res Ayurveda Pharma* 2013; 4(3): 447-451.