

## Treatment of wrist ganglion through Individualised Homoeopathic Medicine – A Case Report

Mehadi Arif Billah,<sup>1\*</sup> Binoy Pratap Singh<sup>2</sup> Shikha Dubey<sup>3</sup>

<sup>1</sup> PG Scholar of Dept. of Homoeopathic Materia Medica, <sup>2</sup> PG Scholar of Dept. of Case taking and Repertory, <sup>3</sup> Intern doctor, National Institute of Homoeopathy, Govt. of India, Kolkata, India

### ABSTRACT:

Wrist ganglion is a benign disorder of middle age persons characterised by smooth round to oval tense swelling resulting from mucoid degeneration of synovial sheath around the tendon on back of wrist. Other system of medicines mainly focuses on surgical excision, aspiration, steroid administration, sclerotherapy etc but recurrence rate is high. This case study explores the effectiveness of homoeopathy in the treatment of wrist ganglion. This is a case of 18-yr-old female presenting with firm cystic swelling (2cm x 2cm) on dorsum of right wrist, painful on movement of wrist, gradually increasing in size for 3 years. The case was clinically diagnosed as wrist ganglion. Through the totality of symptoms and repertorisation, one dose of Sulphur in 200 centesimal potency was given and after a period of two and a half months, a second dose of Sulphur in the same potency was administered. After medication gradually size of the ganglion reduced and within 4 months of span the ganglion completely disappeared along with pain and other complaints.

**KEY WORDS:** Cyst, Ganglion, Sulphur in 200 centesimal potency.

Received: 16.04.2023 Revised: 03.06.2023 Accepted: 10.06.2023 Published: 16.06.2023

### Quick Response code



### \*Corresponding Author:

**Dr. Mehadi Arif Billah**

B.H.M.S; PG Scholar of Dept. of Homoeopathic Materia Medica, National Institute of Homoeopathy, Kolkata.

Email: [arifmehadi@gmail.com](mailto:arifmehadi@gmail.com)

### INTRODUCTION:

Wrist ganglion is a benign disorder of middle age persons characterised by smooth round to oval tense swelling resulting from mucoid degeneration of synovial sheath around the tendon on back of wrist. [1] Ganglion is a discrete, [2] tense, cystic, swelling and occurs due to myxomatous or mucoid degeneration of synovial sheath lining the joint or tendon sheath. [3-4] They are common around joints because of abundant fibrous tissue. They contain gelatinous fluid. [5] It varies from the size of a small pea to a large marble.

The ganglion is a type of false cyst because it does not have any epithelial lining. [6] The fluid accumulation is the result of exudation or degeneration. The most common site is dorsum of the hand at the scapholunate articulation. It also occurs in the foot around ankle joint, flexor aspect of fingers etc. [7]

It occurs most commonly in middle aged people between 20-50 yrs of age. It presents with round to oval swelling with smooth surface and round borders. No change in skin over the swelling. Swelling feel like tense, cystic, fluctuant in nature with negative transillumination test. Swelling moves in transverse direction. [8] There is no

specific cause but it occurs most commonly in women. Some of the risk factors are osteoarthritis, injury to joint or tendon etc. The two main concern patients have either the cosmetic appearance or they were concerned that their ganglion is a malignant growth. As per statistics 19.5% patients had symptoms other than a mass. 26% consulted because of pain. 8% consulted because of altered sensation or restricted hand functions.<sup>[9]</sup>

The ganglion is mainly diagnosed by clinically. X-Ray will not show a ganglion cyst. They can be used to rule out other conditions such as arthritis of hand, wrist or bone tumour. MRI is best method to diagnose small impalpable dorsal wrist ganglion. In other system of medicine treatment is mainly based on surgical and non-surgical like aspiration, steroid administration, sclerotherapy, hyaluronidase injection, immobilisation etc. Post surgical recurrence rate is around 4% - 40%.<sup>[10]</sup> The success rate of non-surgical treatment is also very less.

#### **CASE REPORT:**

An 18 years old female from KLC, South 24(PGS), West Bengal, attended the outdoor patient department (OPD) of the National Institute of Homoeopathy, Kolkata on 01/09/2021 with her guardian. She complained of swelling on back of right wrist (2cm x 2cm), painful on movement of wrist gradually increasing in size for 3 years. She had taken several allopathic drugs but no change occurred. So mainly for cosmetic appearance and pain in wrist she

consulted. After full case taking we got that warm is intolerable to her (hot patient). She likes sweets. Her appetite was more. She was very much anxious in nature. History of suppressed skin eruption 5 years ago. Clinical examination showed mobile, fluctuant, round cystic swelling on dorsum of wrist around 2\*2 cm. Transillumination was negative. Skin around swelling was normal.

#### **Totality Of Symptoms:**

1. Anxious in nature
2. Intolerance to warm (hot patient)
3. Desire for sweets
4. Appetite increased
5. Wrist ganglion
6. Pain in right wrist

#### **Repertorisation**

The Synthesis Repertory was chosen because the case contains full of general as well as particular symptoms.

#### **Repertorial analysis**

Sulphur 14/6, Rhus Tox 10/6, Ruta 7/6, Lycopodium 13/5.<sup>[11]</sup> After repertorisation Sulphur covered all the rubrics with highest marks also it is supported by presence of suppressed skin eruption in past history. So after consultation with materia medica Sulphur was prescribed.

#### **Prescription**

1<sup>st</sup> Prescription on 01/09/2021

Rx

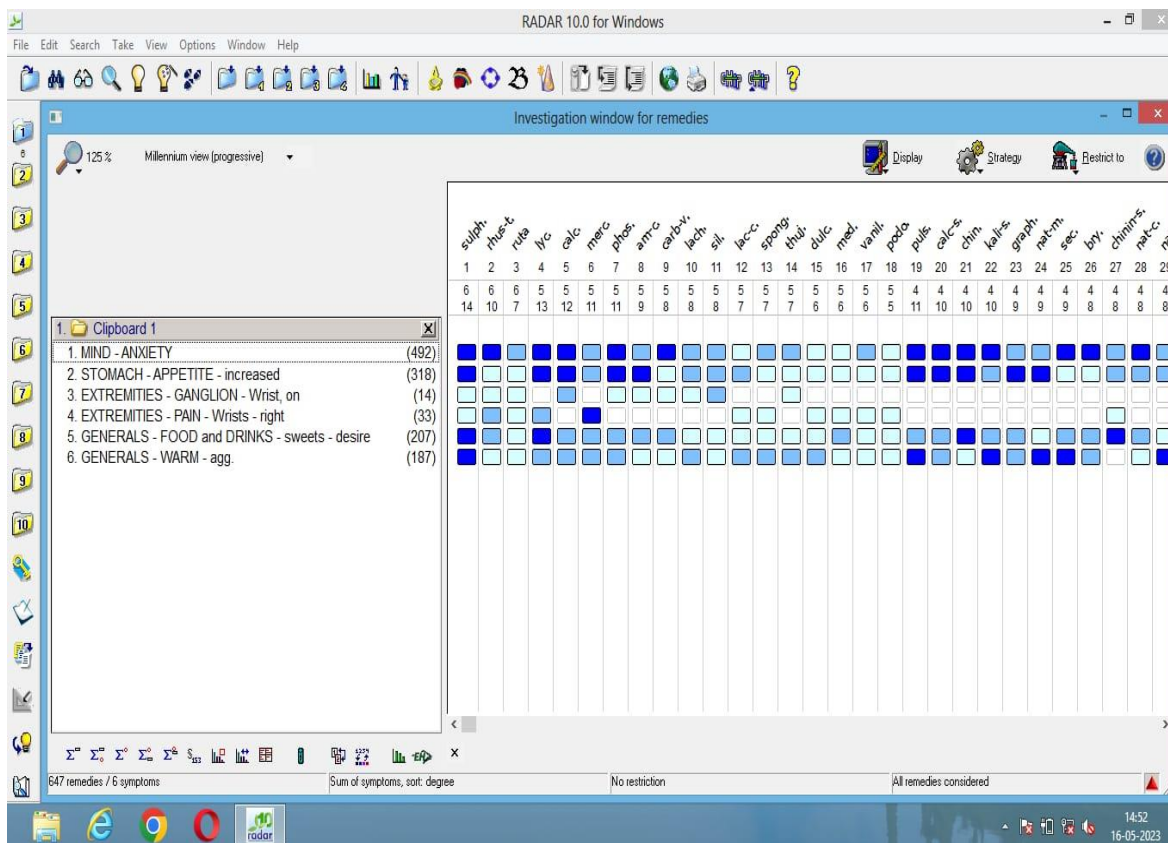
Sulphur 200, one dose in sugar of milk.

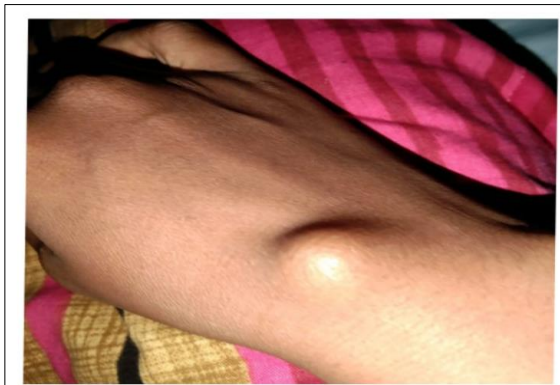Placebo 30 doses, OD\*30 days.

**Table-1: Follow up:**

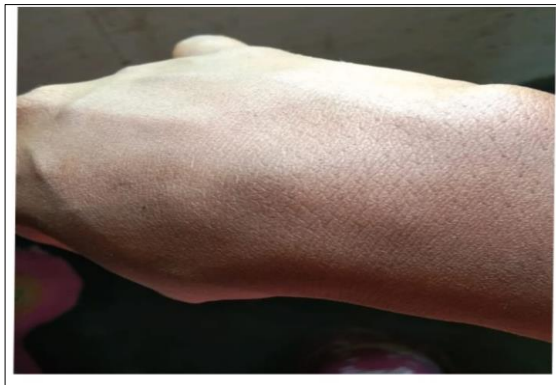Date	Symptoms	Treatment prescribed
20/10/2021	Patient is feeling better. Anxiety level is same. Size of ganglion slightly reduced. Pain on movement of wrist slightly decreased.	Placebo 30 doses, OD*30 days
17/11/2021	Patients condition is standstill. Anxiety level slightly reduced. Size of ganglion same as last visit. Pain on movements same as last visit.	Sulphur 200, one dose in sugar of milk. Placebo 30 doses, OD*30 days
29/12/2021	Patient is as a whole better. Anxiety level decreased. Ganglion almost disappeared. Pain during movement of wrist disappeared. Clinically no presence of ganglion on wrist.	

**REPERTORISATION CHART**





**Fig-1: Wrist Ganglion On 01/09/2021**



**Fig-2: Wrist Ganglion On 29/12/2021**

### DISCUSSION

Wrist ganglion is one of the cosmetic problems as well as troublesome when it gives pressure symptoms. In conventional medicine, surgical intervention is often recommended for ganglion cysts that cause pain or functional impairment. However, surgical procedures come with associated risks such as infection, scarring, and the possibility of recurrence.<sup>[10]</sup>

Aspiration, another conventional approach, involves removing the cyst's fluid with a needle. However, this procedure may also lead to recurrence and is not always effective in addressing the root cause of the cyst.<sup>[12]</sup> Homeopathy is a safe, non-invasive, and cost-effective alternative to conventional treatments. Homeopathic remedies are known to address the underlying causes of the cyst, potentially reducing the likelihood of recurrence and offering a long-term solution.

The success of individualized medicine in centesimal potency for treating wrist ganglion is demonstrated by the presented case. Homeopathy offers an inexpensive, holistic and individualized approach and this case highlights its effectiveness in treating ganglion cysts.

### CONCLUSION

This case study highlights the potential of individualized Homeopathic treatment for curing wrist ganglion.

### Limitation of the study:

This is a single case report. In future case series can be recorded on effectiveness of individualised Homeopathic medicine in wrist ganglion.

### Consent of patient:

The authors certify that they have obtained appropriate patient consent form and the patient understood her name and initials will not be mentioned in the manuscript and due efforts will be taken to conceal her identity.

### REFERENCES:

1. Chaurasia BD, Garg K. Human anatomy: Regional and Applied Dissection and clinical Vol. 1, Joints of upper limb. CBS Publishers & Co, New Delhi, India. 4<sup>th</sup> edition 2004, pp-156,157
2. Branch WT. Office practice of Medicine. Saunders, Philadelphia, Harvard. 1982, pp-835-836.
3. C. RWH, Mitchiner PH. The science and practice of surgery, The muscles, tendons and bursae. J. & A. Churchill, London, Portman Square. 1934, pp-389,390
4. Shenoy KR, Shenoy A. Manipal Manual of Surgery, Tumours cysts and neck swellings. CBS Publishers & Co, New Delhi. 4<sup>th</sup> Edition 2020, pp-172-177
5. O'Connell PR, McCaskie AW, Sayers RD. Bailey & Love's short practice of surgery,

- Diseases of muscles, tendons and fasciae. CRC Press, Boca Raton, London. 28<sup>th</sup> edition 2023, p-453
6. Chatterjee B. P. A short text book of surgery Vol. 1, Tumours. New Central Book Agency, Calcutta. 1st edition 1971, p-67
  7. McCredie JA, Burns GP. Basic surgery. New York, Toronto: Macmillan; 1990.
  8. Das S. A Manual on Clinical Surgery, Examination of individual joint pathologies.. S. Das Calcutta. 5<sup>th</sup> Edition 2000, pp-175,176
  9. Suen M, Fung B, Lung CP. Treatment of ganglion cysts. ISRN Orthop. 2013 May 28;2013:940615.
  10. Graham JG, McAlpine L, Medina J, Jawahier PA, Beredjikian PK, Rivlin M. Recurrence of Ganglion Cysts Following Re-excision. Arch Bone Jt Surg. 2021 Jul;9(4):387-390.
  11. Synchorne F. Radar. Belgium: Synthesis; 2007. Synthesis Adonis: New Homoeopathy Synthesis Updates: RadarOpus [Last accessed 22.07.2022]
  12. Townsend CM, editor. Sabiston textbook of surgery: The biological basis of modern surgical practice, Hand Surgery. Elsevier - Health Sciences Division, Philadelphia. 21<sup>st</sup> edition 2021, p-1981.
- Conflict of interest:** Author declares that there is no conflict of interest.
- Guarantor:** Corresponding author is guarantor of this article and its contents.
- Source of support:** None
- How to cite this article:**  
Mehadi AB.Singh BP. Dubey S. Treatment of wrist ganglion through Individualised Homoeopathic Medicine – A case report. Int. J. AYUSH CaRe. 2023;7(2): 158-162.