

## Efficacy of individualized homeopathic treatment in the management of Dermatophytosis- A Case Series

Poulamy Singharoy<sup>1</sup>, Salema Naaz Tabassum<sup>1</sup>, Smriti Das<sup>2</sup>, Vedajit Fouzdar<sup>3</sup>, Anupam Hazra<sup>3</sup>, Pritam Goswami<sup>2\*</sup>

<sup>1</sup> Post Graduate Trainee, Dept. of Materia Medica, Mahesh Bhattacharyya Homoeopathic Medical College and Hospital, Howrah, West Bengal 711104, India

<sup>2</sup> Post Graduate Trainee, Dept. of Repertory, Mahesh Bhattacharyya Homoeopathic Medical College and Hospital, Howrah, West Bengal 711104, India

<sup>3</sup> Independent researcher, Mahesh Bhattacharyya Homoeopathic Medical College and Hospital

### Abstract:

The 'Skin' has its own cosmetic values other than normal physiological functions. Dermatophytosis is a superficial skin infection causing annular itchy lesions on the superficial skin surface. A steady escalation in the burden of fungal disease has emerged in the form of an epidemic in India. Lack of awareness among the common people subjugated with poor hygiene, low socioeconomic status, humid weather conditions of the tropics, and subtropics contributes to worsening the present scenario. Lack of research in mycology and misuse of the combination of steroid and anti-fungal has led to an uncontrolled outbreak of the disease with diverse clinical symptoms in different age groups. This case series shows 5 different cases of Dermatophytosis treated in the Outpatient departments. 3 out of 5 cases were less responsive to the conventional anti-fungal ointments which lead the patient to opt for Homoeopathy. All 5 cases recovered with individualised homoeopathic treatment without any further complications. The situation demands a well thought alternative treatment option that can reduce the disease burden and the financial burden. This evidence gives a positive direction for the application of homeopathy alone and seems to open a door for add-on therapies along with conventional treatments in the future.

**Key Words:** Anti-fungal, Dermatophytosis, Homoeopathy, Ring worm.

Received: 07.10.2021 Revised: 09.11.2021 Accepted: 06.12.2021 Published: 25.12.2021

Quick Response code



**\*Corresponding Author:**

**Dr. Pritam Goswami**

Post Graduate Trainee, Dept. of Repertory,  
Mahesh Bhattacharyya Homoeopathic Medical  
College and Hospital Howrah, West Bengal  
711104, India

E-mail : [pgoswami225@gmail.com](mailto:pgoswami225@gmail.com)

**Introduction:**

Superficial skin infection can be caused by several dermatophytes, non-dermatophytes moulds, and yeasts. [1] Dermatophytes are filamentous fungi that commonly reside on soil and affects superficial skin, nails, and hairs. This type of infestation is popularly known as Dermatophytosis. In some conditions, the lesion spreads all over the body with increased social and psychological burden subjugated with increased severity of the illness affecting the quality of life. [2]. According to WHO the prevalence of superficial mycotic infection globally was 20-25% in 2015. [3] Dermatophytes were common but it was never given such serious importance in research but the steady escalation in the last few years has changed the global scenario. In India, the prevalence of dermatophytosis ranges from 36.6%-78.4% which is an alarming condition. [4]

The clinical spectrum of the presentation varies largely as observed by dermatologists unusual large lesions, ring within ring lesions, multiple site lesions, and corticosteroid modified lesions, making diagnosis and remission difficult. [5] In addition to this uncontrolled recurrence added to the form of chronicity has caused more panic and plagued the patients. The organisms that predominate in India are *Trichophyton rubrum*, *Trichophyton mentagrophytes*, and *Microsporum gypseum* but there have been reports showing an increase in *T. mentagrophytes* as a leading causative agent in many studies. [6-8] Along with neglected approaches, the climate pattern of tropics and subtropics with high humidity and temperature increased moisture, poor hygiene provides fertile soil for the fungus. [9,10] Long continued treatment and cost of medication often lead the patient to search for alternative therapies. Homeopathy is the second most popular mode of treatment following modern medicine. Lack of an established mechanism of action of homeopathic drugs always hinders its' acceptance among the scientific world. Poor

infrastructure, lack of awareness, and neglected reporting of cases also play a pivotal role to turn down shreds of evidence in favour of homeopathy. Dermatophytosis or colloquially known as "ringworm" is being treated in the OPD and private clinics by homeopaths for many years but it has perpetually remained unnoticed. Here in this case series, five different cases of dermatophytosis were treated by homeopathic treatment successfully.

**Case 1:** A 45 years old female patient came to OPD in the month of August of 2020 with the complaints of dry, itching eruption at lower part of the chest and abdomen, from last 15 days. Itching was getting relieved by application of cold water and worse by sun heat. The patient also narrated that she had similar kind of lesion on her groin 5 years back but it was cured by allopathic medicines while examining several lesions were observed and no discharge was seen from the affected area. After careful examining the affected areas, the lesion was diagnosed as tinea corporis (Figure-1).

**General symptoms (Physical and Mental):**

Her appetite was moderate but better in empty stomach, with great thirst. She had desire for fish, salty food with a habit of regular early morning, evacuation. Urine clear but it was difficult for the patient to hold the urge of urine. The patient prefers cold weather and palms were hot and moist. Tongue showed slight white coating. Face sweats typically more than any other region of the body. She was irritable, sentimental, has weeping disposition.

**Analysis of the case:** After analysing the case, characteristic mental and physical symptoms taken to form the totality of symptom and we went for Repertorisation (Figure-16) with Kent's repertory by using Zomeo 3.0.

**Prescription:** Considering miasm and totality of symptoms Natrum muriaticum 30 / 2 doses were prescribed with showed little improvement in the area of lesion with marked reduction of itching. It was followed by 2 doses of Natrum muriaticum 200 was prescribed to achieve cure (Figure -2). A detailed timeline of the treatment has been discussed in Table-1.

**Case 2:** A 25 years old female patient came to OPD with the complaints of dry, circular itching eruption at abdomen and buttock for last 2 months. The patients initially went for conventional therapy but certainly it didn't improve the condition which led the patient to homoeopathy. On further examination we noticed annular patchy lesions which helped us to diagnose the case as Tinea cruris and Tinea Corporis (Figure-3,4,), another clinical form of dermatophytosis.

On further enquiry regarding the symptoms we were told that the itching is ameliorated by cold air and after undressing and aggravated by washing or bathing and after exposure to sweat. Patient also narrated that there was same itchy, dry eruption 6 months ago, which was treated by using ointments, without consulting any dermatologists.

**General Symptoms (Physical and Mental):** Her appetite was good and empty stomach causes headache. She desire for sweets, meat, cold food and drinks. Thirst was moderate (drink water only when eating food). Patient also complained about burning of palms and soles with intolerance of heat. Patient sweats profusely which aggravates her complaints. Her tongue was slightly coated with no association of menstrual irregularities. Her sleep was disturbed due to itching of the affected area.

**Analysis of the case:** After analysing the case, characteristic mental and physical symptoms taken to form the totality of symptom and we

went for Repertorisation (Figure-17) with Kent's repertory by using Zomeo 3.0.

**Prescription:** Sulphur 30, 2 doses were prescribed followed by placebo for 15 days. It was instructed to take medicine early morning in empty stomach. After first prescription as the patient was improving (Figure 5,6) then she was given placebo but at one point Sulphur 30; 2 doses were prescribed to achieve cure (Figure 7,8). A detailed time line of the treatment has been mentioned in Table 2.

**Case 3:** A 21 year old male patient came to OPD with the complaints of itching with eruption around his buttock area as well as lower part of the back. The patient was suffering from last one year and he has been treated with anti-fungal medicines along with ointments. His eruption was dry, circular ring like patches with severe itching at night and he was getting relief by application of cold water. After examination we diagnosed the case as Tinea cruris (Figure 9).

**General symptoms (Physical and Mental):** We further enquired to know that, his appetite is good. The patient was having a great desire towards sweet & aversion towards fish. No such complaints regarding stool and urine were noted. He had a profuse perspiration on his head which was not offensive. Sleep was undisturbed and no specific complaints were noted regarding his sleeping habits. He was least tolerant to cold weather or wind and the patient was irritable, but prefers to be with family and company of others.

**Analysis of the Case:** After analysing the case, characteristic mental and physical symptoms were taken to form the totality of symptom and individualize the case. We considered characteristic mental and physical symptoms taken to form the totality of symptom and we went for Repertorisation (Figure-18) with Kent's repertory by using Zomeo 3.0.

**Prescription:** Tuberculinum 200CH, 2 doses and was instructed to take once daily in the morning for 2 days in empty stomach followed by Rubrum. Patient showed gradual improvement but occasional paroxysms with mild to moderate flaring up of symptoms led us to prescribe Tuberculinum 1M, one dose followed by placebo (Figure 10). A detailed timeline of the treatment has been mentioned in Table -3.

**Case 4:** A 33 year old female patient came to OPD with the complaints of itching with eruption on her right wrist (Figure 11). The patient has developed from last 2 weeks and on careful history taking she told that she had similar lesion on her groin which got cured after taking conventional therapies. Her eruption was moist with oozing of sticky fluid and the skin had a tendency to break of that particular area. Her itching was better from application of warmth.

**General Symptom (Physical and Mental):** Her appetite was good and she was thirst less. The patient was having a great aversion towards sweet & meat, desire for fish and warm food was there. Perspiration was less with slight offensiveness present. Regarding stool and urine no complaints noticed. Sleep was undisturbed and devoid of any dreams during. Mentally the patient was timid with a desire to be alone because of her illness.

**Analysis of the Case:** After analysing the case, characteristic mental and physical symptoms were taken to form the totality of symptom and individualize the case. We considered characteristic mental and physical symptoms taken to form the totality of symptom and we went for Repertorisation (Figure-19) with Kent's repertory by using Zomeo 3.0.

**Prescription:** Graphites 30CH, 2 doses and was instructed to take once daily in the

morning for 2 days in empty stomach followed by Rubrum for next 15 days in the similar way. In this case we observed marked improvement with reduction in the affected area and itching (Figure-12). The detailed timeline of the treatment has been given in Table -4.

**Case-5:** A 48 year old female patient came to OPD with the complaints of circular eruptions in the neck and back from last 7 days (Figure-13). In this case the patient had positive history of similar dermatophytosis 2 years back, which was treated by homoeopathic medicines. On further enquiry we got to know that the patient had recovered from mild Covid-19 disease for which she was in home isolation. After 2 weeks of remission of Covid-19 annular lesion has reappeared in the neck and back.

**General Symptom (Physical and Mental):** The patient complained about loss of appetite and she could drink water. The patient was having a great aversion to every kind of food. Perspiration was profuse with aggravation of the complaints during. Sleep was disturbed due to aggravation of itching at night. The patient was more sensitive to hot applications and heat of bed. Also unusual anxiety regarding the complaint was noticed. Marked feature of prostration was noticed in the patient.

**Analysis of the case:** Careful analysis of the characteristic mental and physical symptom was used to form the totality of symptom without any help of repertory. As the patient has previously suffered from Covid 19 so she was also advised to take plenty of water and nutritious diet to get over from the prostration.

**Prescription:** Rhus Toxicodendron 30CH, 4 doses and was instructed to take once daily in the morning for 2 days in empty stomach followed by Rubrum for next 15 days. Mild improvement noticed with reduction in

intensity of itching (Figure-14). Later the patient treated with Sulphur 30, 2 doses with subsequent doses of placebo for 1 month,

which helped in complete removal of the lesion (Figure-15). The detailed timeline of the treatment has been given in Table -5.

**Table -1: Prescription and Timeline of case -1:**

Date of visit	symptoms	Medicines Prescribed
10/8/2020	Dry itching eruption at abdomen and lower part of the chest, > cold application, < sun heat	Natrum muriaticum 30 / 2doses followed by placebo for 15 days
24/8/2020	No itching, area of eruption increased	Placebo for next 30 days
21/9/2020	Patient became stand still	Natrum muriaticum 200/2 doses and followed by placebo
5/10/2021	No eruption, no itching	Placebo

**Table -2: Prescription and timeline of Case-2:**

Date of visit	Symptoms	Medicines prescribed
3/2/2020	Dry, violent itching, circular eruption at abdomen and buttock,> cold air, undressing, < washing or bathing, sweating.	Sulphur 30/2 doses followed by placebo
17/2/2020	Itching slightly reduced	Placebo
2/3/2020	No itching, area of eruption reduced	Placebo
16/3/2020	Itching slightly increased	Sulphur 30/ 2 doses, followed by placebo
30/3/2020	No itching	Placebo
13/4/2020	No itching, no eruption	Placebo
18/5/2020	No itching, no eruption, patient cured	Placebo

**Table -3: Prescription and timeline of Case-3:**

Date of visit	Presenting Complaint	Medicines Prescribed
04/01/2021	Intensive itching with eruption around his buttock area as well as lower part of the back.<night, >cold water	Tuberculinum200CH/2doses+PL/15D
18/01/2021	Itching was same but the eruption started fading away.	Rubrum for next 15 days.
01/02/2021	Itching was decreased much and eruption was also decreased, right sided buttock was fully cleared.	Rubrum for next 28 days.
01/03/2021	Itching was same, left sided eruption on buttock was same and again there was a tiny eruption coming out at right side.	Tuberculinum1M/1dose+PL/28D



29/03/2021	Itching was much decreased and eruption on right side was completely gone. On left side there was still eruption persists.	Rubrum for next 15 days.
19/04/2021	There was no itching with much relief to the patient. No eruption was persists on either side of the buttock.	Rubrum for next 28 days.

**Table -4: Prescription and Timeline of Case-4:**

Date of visit	Symptoms	Medicines Prescribed
03/03/2021	Moist eruption with oozing of sticky fluid from right wrist.	Graphites 30 CH/ 2 doses +placebo / 15 doses
17/03/2021	No eruption, no itchiness	Placebo

**Table -5: Prescription and Timeline of Case-5:**

Date of visit	Symptoms	Medicines Prescribed
05/04/2021	Large annular lesion in the neck and back with severe itching aggravated from hot application and at night.	Rhus toxicodendron 30 CH/ 4 doses +placebo / 15 doses
20/04/2021	No new lesion seen but Itching persisted which was relieved after cold application	Sulphur 30CH/2 doses followed by Placebo for 15 days
05/05/2021	Patches dried up, Itching reduced markedly. Post covid19 prostration reduced markedly	Placebo was given for 15 Days
20/05/2021	Patches almost disappeared with complete relief of itching and no further new lesion appeared.	No further medicine given

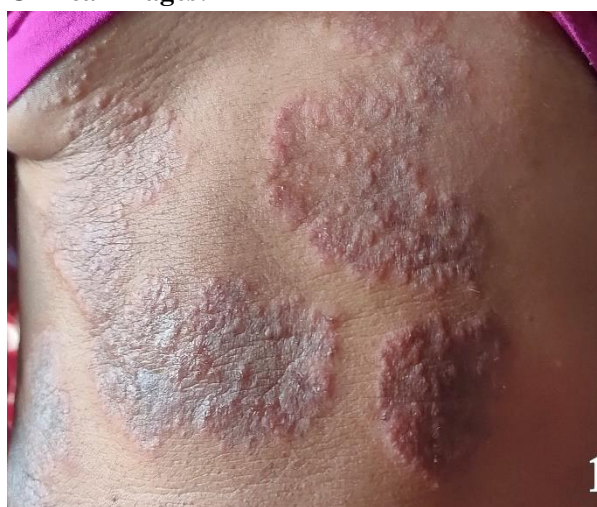**Clinical images:**


Figure-1: Circular lesion in the anterior aspect of abdomen and chest in case-1

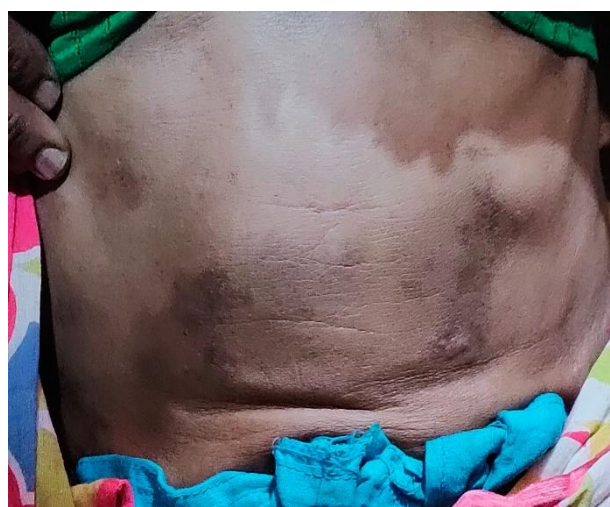

Figure-2: Establishment of normal skin mucosa after successful treatment.

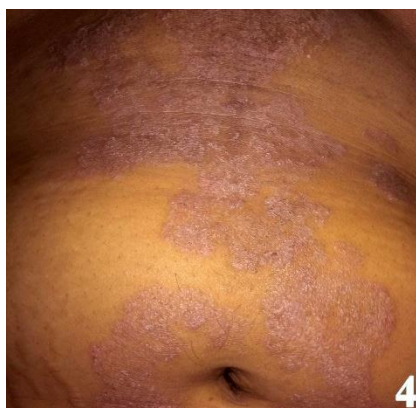
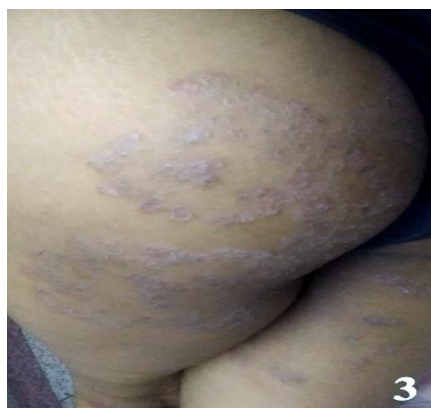
Figure- 3&4 Lesion before the treatment in case-2

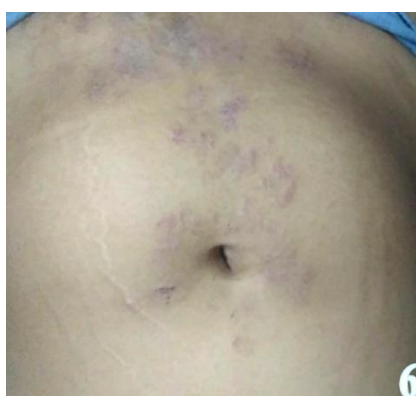
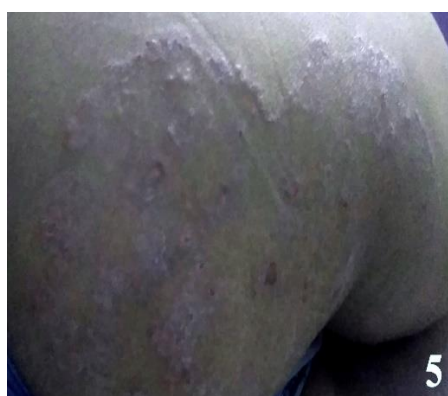
Figure 5&6: Appearance of the lesion during the treatment in case-2

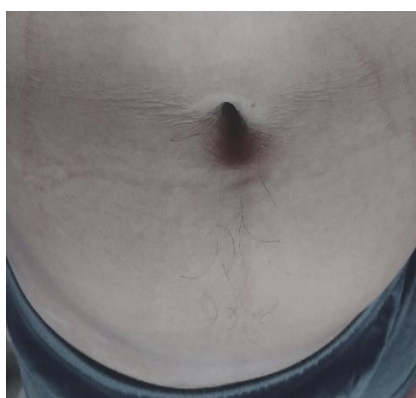
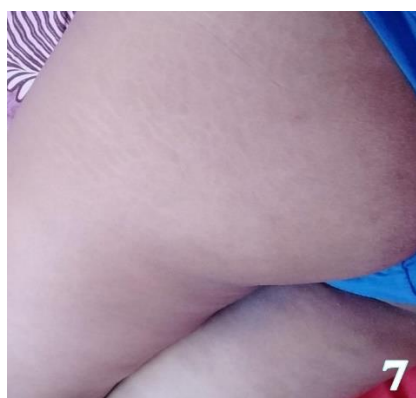
Figure 7&8: Disappearance of the patches at the end of treatment in case-2

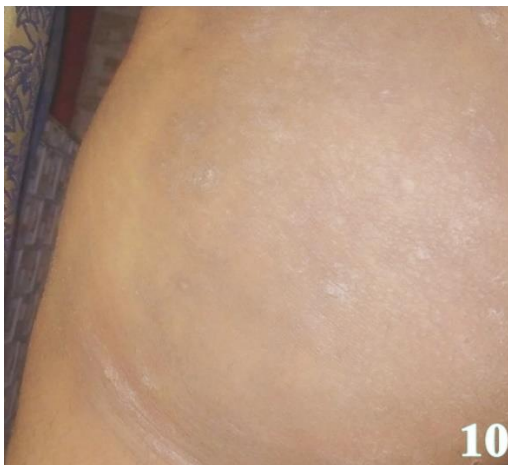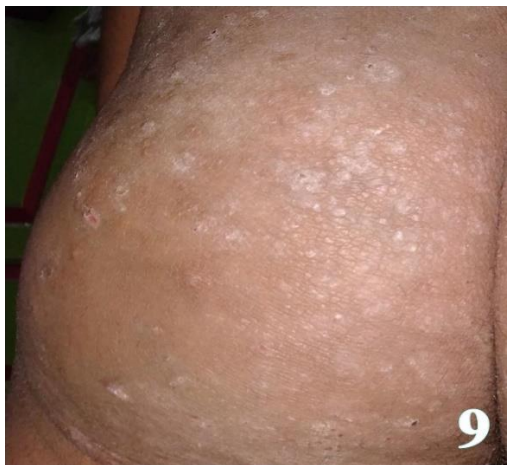


Figure 9 & 10: Appearance of the lesion before and after the treatment in case -3

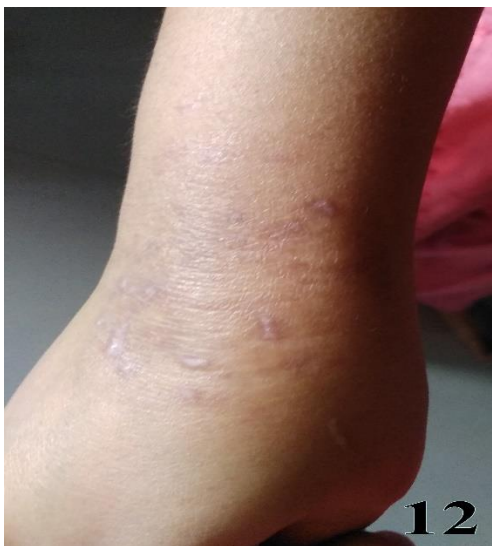
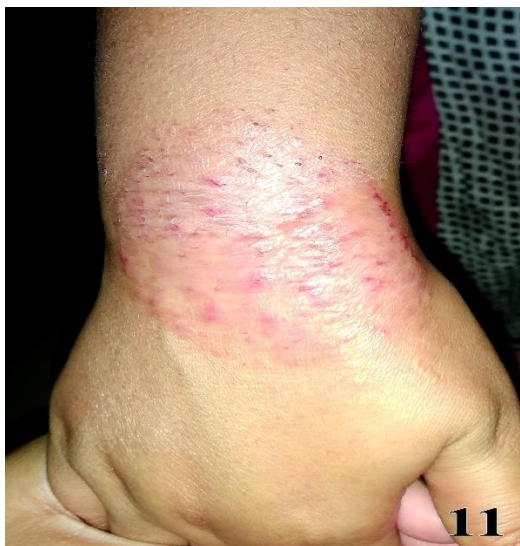
Figure-11 &12: Change in appearance of circular lesion at the wrist before and after treatment in case-4

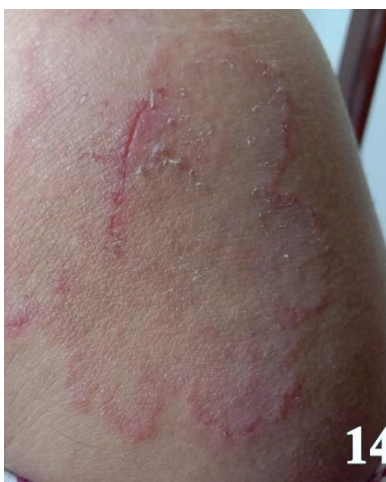
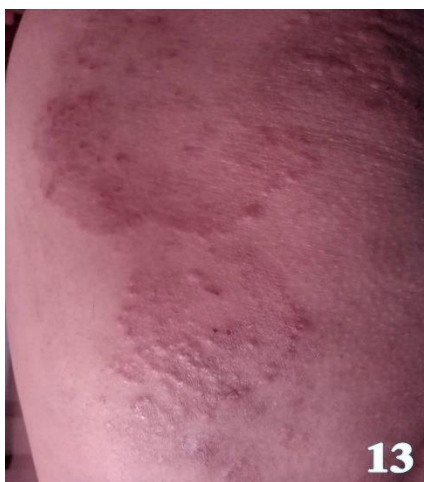
Figure-13: annular atches at the shoulde and back before treatment in case-5.

Figure 14 Mild improvement during the course of treatment



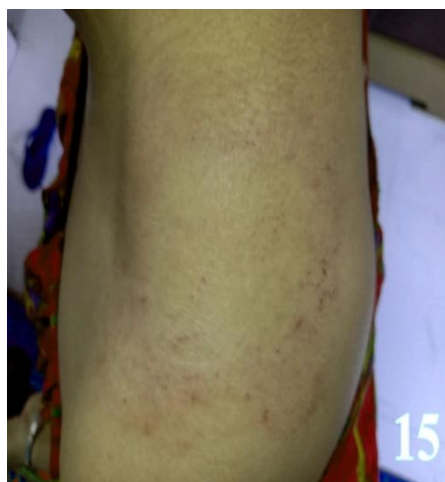


figure 15 Remission of the lesion after completion of the treatment.

Repertorisation Sheet - Zomeo 3.0																				
Physician Name : Dr. SMRITI DAS , Patient Name : , Reg. No. : , Date : 01/05/2021																				
Remedy	Nat-m	Phos	Calc	Calc-p	Sulph	Carb-v	Lyc	Nux-v	Verat	Arg-n	Ign	Puls	Sep	Cocc	Con	Acon	Calc-s	Psor	Alum	Ant-c
<b>Totality</b>	16	15	14	13	13	13	13	12	12	11	11	11	11	10	10	10	10	10	10	10
<b>Symptoms Covered</b>	6	7	6	6	6	5	5	5	5	5	5	4	4	6	6	5	5	5	4	4
[Kent ] [Generalities]Cold:Tendency to take:	3	2	2	3	2	2	3	3	1	2	1	2	3	1	2	3	2	3	3	2
[Kent ] [Stomach]Desires:Fish:	2	1	0	0	0	0	0	0	0	0	0	0	0	0	0	0	0	0	0	0
[Kent ] [Stomach]Desires:Salt things:	3	3	2	2	1	3	0	0	3	3	0	0	0	1	2	0	1	0	0	0
[Kent ] [Mind]Irritability (see anger):	3	3	3	2	3	3	3	3	2	2	1	3	3	2	2	3	3	2	3	3
[Kent ] [Mind]Weeping,tearful mood,etc.:	3	2	3	2	3	2	3	2	3	2	3	3	3	2	2	2	3	1	2	2
[Kent ] [Mind]Sentimental:	0	2	1	2	2	0	1	1	0	0	3	0	0	2	1	1	0	2	0	3
[Kent ] [Face]Perspiration:	2	2	3	2	2	3	3	3	3	2	3	3	2	2	1	1	1	2	2	0

Figure 16: Repertorial analysis of case-1:

Repertorisation Sheet - Zomeo 3.0																				
Physician Name : Dr. SMRITI DAS , Patient Name : , Reg. No. : , Date : 01/05/2021																				
Remedy	Sulph	Lyc	Nat-m	Kali-s	Phos	Merc	Kali-c	Mag-c	Puls	Nux-v	Petr	Sabad	Arg-n	Bry	Calc	Calc-s	Carb-v	Chin	Lil-t	Mang
<b>Totality</b>	11	8	7	7	7	6	6	6	6	5	5	5	5	5	5	5	5	5	5	5
<b>Symptoms Covered</b>	5	3	5	3	3	4	3	3	2	3	3	3	2	2	2	2	2	2	2	2
[Kent ] [Stomach]Desires:Sweets:	3	3	1	2	0	1	2	0	0	1	1	2	3	2	2	2	2	3	0	0
[Kent ] [Stomach]Desires:Meat:	1	0	1	0	0	1	0	2	0	0	0	1	0	0	0	0	0	0	2	0
[Kent ] [Stomach]Desires:Cold:Food:	0	2	1	2	3	0	0	0	3	0	0	0	0	0	0	0	0	0	0	0
[Kent ] [Stool]Watery:Morning:	3	0	1	0	1	0	1	1	0	1	1	0	0	0	0	0	0	0	0	0
[Kent ] [Skin]Eruptions:Itching:Cold air:Air amel:	0	0	0	0	0	0	0	0	0	0	0	0	0	0	0	0	0	0	0	0
[Kent ] [Skin]Eruptions:Itching:Washing:Agg:	1	0	0	0	0	0	0	0	0	0	0	0	0	0	0	0	0	0	0	0
[Kent ] [Skin]Itching:Perspiration agg:	0	0	0	0	0	2	0	0	0	0	0	0	0	0	0	0	0	0	0	3
[Kent ] [Mind]Irritability (see anger):	3	3	3	3	3	2	3	3	3	3	3	2	2	3	3	3	3	2	3	2

Figure 17: Repertorial analysis of case-2:

Repertorisation Sheet - Zomeo 3.0																				
Physician Name : Dr. SMRITI DAS , Patient Name : , Reg. No. : , Date : 01/05/2021																				
Remedy	Phos	Kali-c	Calc	Graph	Sep	Nux-v	Sil	Petr	Tub	Psor	Agar	Con	Nat-c	Dulc	Am-c	Tarent	Mag-c	Cocc	Mosch	Am-m
<b>Totality</b>	17	16	15	14	14	13	12	10	9	9	8	8	8	8	6	6	6	5	5	4
<b>Symptoms Covered</b>	7	6	6	6	6	6	4	5	5	4	5	4	4	3	4	4	3	3	3	3
[Kent ] [Generalities]Cold:Tendency to take:	2	3	2	2	3	3	3	2	3	3	0	2	2	3	1	0	0	1	0	1
[Kent ] [Stomach]Desires:Sweets:	0	2	2	0	2	1	0	1	2	0	0	0	2	0	2	0	0	0	0	0
[Kent ] [Generalities]Heat:Vital,lack of:	3	3	3	3	2	3	3	2	2	3	2	2	1	3	2	2	2	2	2	2
[Kent ] [Mind]Irritability (see anger):	3	3	3	3	3	3	3	3	1	2	2	2	3	2	1	2	3	2	1	1
[Kent ] [Head]Perspiration:Scalp:	3	2	3	2	2	1	3	2	1	1	2	0	0	0	0	1	1	0	2	0
[Kent ] [Back]Itching: Sacrum:	0	0	0	1	0	0	0	0	0	0	0	1	0	0	0	0	0	0	0	0
[Kent ] [Back]Itching:Night:	1	0	0	0	0	0	0	0	0	0	1	0	0	0	0	0	0	0	0	0
[Kent ] [Stomach]Aversion:Fish:	2	0	0	3	0	0	0	0	0	0	0	0	0	0	0	0	0	0	0	0
[Kent ] [Mind]Company:Desire for:	3	3	2	0	2	2	0	0	0	0	0	2	0	0	0	1	0	0	0	0

Figure 18: Repertorial analysis of case-3:

Repertorisation Sheet - Zomeo 3.0																				
Physician Name : Dr. SMRITI DAS , Patient Name : , Reg. No. : , Date : 01/05/2021																				
Remedy	Phos	Graph	Ars	Nat-m	Nit-ac	Sulph	Nux-v	Sep	Merc	Kali-c	Lyc	Sil	Caust	Mez	Chin	Ferr	Calc	Sabad	Alum	Carbn-s
<b>Totality</b>	14	14	13	13	13	13	13	13	12	12	12	12	11	11	11	11	11	10	10	10
<b>Symptoms Covered</b>	7	5	6	6	6	6	5	5	6	5	5	4	6	6	5	5	4	5	4	4
[Kent ] [Generalities]Cold:Tendency to take:	2	2	1	3	3	2	3	3	3	3	3	3	1	1	1	2	2	1	3	2
[Kent ] [Stomach]Thirstless:	1	0	2	1	1	1	1	2	0	2	2	0	1	1	3	2	0	3	0	0
[Kent ] [Stomach]Aversion:Sweets:	2	3	2	0	1	2	0	0	2	0	0	0	2	0	0	0	0	0	0	0
[Kent ] [Stomach]Aversion:Meat:	2	3	2	2	2	3	3	3	2	2	2	3	1	2	3	2	3	2	2	3
[Kent ] [Stomach]Desires:Fish:	1	0	0	2	0	0	0	0	0	0	0	0	0	0	0	0	0	0	0	0
[Kent ] [Generalities]Heat:Vital,lack of:	3	3	3	2	3	2	3	2	2	3	2	3	3	2	2	3	3	2	2	2
[Kent ] [Rectum]Constipation (see inactivity):	3	3	3	3	3	3	3	3	2	2	3	3	3	3	2	2	3	2	3	3
[Kent ] [Extremities]Eruption:Wrists:Itching:	0	0	0	0	0	0	0	0	1	0	0	0	0	2	0	0	0	0	0	0

Figure 19: Repertorial analysis of case-4:

**Discussion:**

Though the current situation seems to be demanding new research pathways only for SARS CoV-2 behind the curtain exponential growth of fungal infections should not be neglected as it seems like India is fighting another epidemic related to fungal infections. [11-12]. Dermatologists across the world are well aware of the scenario but the situation is not managed by dermatologists only. Conditions like low socio-economic status, poverty, immune-compromised states like diabetes, HIV presents new therapeutic challenges in day-to-day practice which makes them difficult to eradicate fungal infections. [13-14] Mycology is a neglected field of research in medical science.

As per WHO misuse of anti-fungal medicines both oral and fixed drug combination ointments have played a pivotal role in the present scenario. It is noteworthy that in India the sale of anti-fungal creams amounts to Rs. 1040 crores and for antifungal steroid combinations it is approximately 1,310 crores. [15] Patients mostly use these combinations without consulting doctors which worsens the scenario and complicates the disease prognosis and also increases the financial burden. Homeopathy is a very popular alternative treatment option following conventional therapies. Though the anti-fungal effect of Sulphur and Graphites against *Candida albicans* has been demonstrated in an in vitro experiment if they can retain similar activity

against *Trichophyton sp.* is yet to be discovered. [16]

Homeopathy being a popular choice of treatment has always been turned down by the scientific fraternity due to the unknown mechanism of action of homeopathic medicines. [17]. Claims made by homeopathic societies most of the time faces the greatest criticisms due to a lack of acceptable scientific pieces of evidence. As far our knowledge this is the first case series of homeopathy showing its efficacy in dermatophytosis which sets a potential platform for future in-vitro and in-vivo studies to assess the effectiveness of homeopathic medicines in dermatophytosis.

#### **Conclusion:**

This case series somewhat shows a positive direction exploring efficacy of homeopathic medicines in dermatophytosis. In future a potential randomized placebo controlled clinical trials should be done to find better understanding of its scopes and limitations.

#### **Limitation of study:**

Considering the present scenario the present data is not sufficient to make any claim rather it shows the need for good quality, unbiased randomised clinical trial showing efficacy of homeopathic medicines in larger scale for the treatment of dermatophytosis.

#### **Patients Consent:**

All patient's written consent has been taken for treatment and publication of data without disclosing identity of the patient.

#### **Acknowledgements:**

We would like to acknowledge Dept. of Materia Medica and Dept. of Repertory of Mahesh Bhattacharyya Homoeopathic Medical College and Hospital, Howrah, West Bengal.

#### **References:**

1. Gupta CM, Tripathi K, Tiwari S, Rathore Y, Nema S, Dhanvijay AG. Current trends of Clinico mycological profile of Dermatophytosis in Central India. IOSR-JDMS. 2014;13(10):23-6.
2. Gnat S, Nowakiewicz A, Łagowski D, Zięba P. Host- and pathogen-dependent susceptibility and predisposition to dermatophytosis. J Med Microbiol 2019;68:823-6.
3. Lakshmanan A, Ganeshkumar P, Mohan SR, Hemamalini M, Madhavan R. Epidemiological and clinical pattern of dermatomycoses in rural India. Indian J Med Microbiol 2015;33 Suppl 1:S134-6.
4. Naglot A, Shrimali DD, Nath BK, Gogoi HK, Veer V, et al. Recent trends of Dermatophytosis in Northeast India (Assam) and interpretation with published studies. Int J Curr Microbiol App Sci. 2015;4(11):111-20.
5. Dogra S, Narang T. Emerging atypical and unusual presentations of dermatophytosis in India. Clin Dermatol Rev. 2017;1:12-8.
6. Maulingkar SV, Pinto MJ, Rodrigues S. A clinico-mycological study of dermatophytoses in Goa, India. Mycopathologia 2014;178:297-301.
7. Noronha TM, Tophakhane RS, Nadiger S. Clinico-microbiological study of dermatophytosis in a tertiary care hospital in North Karnataka. Indian Dermatol Online J 2016;7:264-71.
8. Mahajan S, Tilak R, Kaushal SK, Mishra RN, Pandey SS. Clinico-mycological study of dermatophytic infections and their sensitivity to antifungal drugs in a tertiary care center. Indian J Dermatol Venereol Leprol 2017;83:436-40.
9. Gadavar S, Shilpa HS, Patil CS, Vinay PS, Shettar N. Clinico-mycological study of dermatophytosis at a tertiary care hospital in Belagavi, Karnataka, India. Int J Curr Microbiol Appl Sci 2018;7:1872-80.

10. Jena AK, Lenka RK, Sahu MC. Dermatophytosis in a tertiary care teaching hospital of Odisha: A study of 100 cases of superficial fungal skin infection. Executive Editor. J Public Health Res Dev 2018;9:7.
  11. Verma S, Madhu R. The great Indian epidemic of superficial dermatophytosis: An appraisal. Indian J Dermatol 2017;62:227-36.
  12. Bishnoi A, Vinay K, Dogra S. Emergence of recalcitrant dermatophytosis in India. Lancet Infect Dis 2018;18:250-1.
  13. Carod JF, Ratsitorahina M, Raherimandimby H, Hincky Vitrat V, Ravaolimalala Andrianaja V, Contet-Audonneau N, et al. Outbreak of tinea capitis and corporis in a primary school in Antananarivo, Madagascar. J Infect Dev Ctries 2011;5:732-6.
  14. Negi N, Tripathi V, Choudhury RC, Bist JS, Kumari N, Chandola I. Clinicomycological profile of superficial fungal infections caused by dermatophytes in a tertiary care centre of North India. Int J Curr Microbiol Appl Sci 2017;6:3220-7.
  15. Verma SB. Complex Cost Issues in Treating Dermatophytoses in India-"It All Builds Up". Indian Dermatol Online J. 2019;10(4):441-443.
  16. Gupta G, Srivastava A K, Gupta N, Gupta G, Mishra S. Anti-candidal activity of homoeopathic drugs: An in-vitro evaluation. Indian J Res Homoeopathy 2015;9:79-85
  17. Cukaci, C., Freissmuth, M., Mann, C. et al. Against all odds the persistent popularity of homeopathy. Wien Klin Wochenschr 2020;132: 232–242.
- Conflict of interest:** Author declares that there is no conflict of interest.
- Guarantor:** Corresponding author is guarantor of this article and its contents.
- Source of support:** None
- How to cite this article:**
- Roy PS, Das S, Goswami P. Efficacy of individualized homeopathic treatment in the management of Dermatophytosis; A case Series. Int. J. AYUSH CaRe. 2021; 5(4):321-332.